

Isistius brasiliensis, A SQUALOID SHARK, THE PROBABLE CAUSE OF CRATER WOUNDS ON FISHES AND CETACEANS

EVERET C. JONES¹

ABSTRACT

Evidence is presented that bites inflicted by the small squaloid shark, *Isistius brasiliensis* (Quoy and Gaimard), are the causes of crater wounds, crescentic wounds, and related scars on large pelagic fishes and cetaceans. This evidence consists of a crescentic "wound" experimentally produced on the side of a dead fish by a living *Isistius*; specialized morphology of the shark's basihyoid cartilage and coracohyoideus muscles, lips, labial cartilages, and spiracles, that, together, enable the shark to form an oral vacuum on a smooth surface; an experiment in which a living *Isistius* formed such a vacuum; specialized morphology and arrangement of the mandibular teeth; close agreement between the range of reported wound widths and the estimated range of bite widths of *Isistius*; agreement between the geographical ranges of *Isistius* and those fishes and cetaceans which bear crater wounds; and, finally, the presence in *Isistius* stomachs of hemispheroidal plugs of fish flesh. Speculation on the circumstances that may enable a small, slow shark to make contact with large, swift fishes and cetaceans is included. *Isistius* apparently qualifies as a temporary parasite.

Probably the earliest account of the existence of small, round or oval, scooped-out wounds on the sides of large pelagic fishes is contained in an ancient legend of Samoa (A. Utu, personal communication), which states that atu (skipjack tuna, *Euthynnus pelamis* (Linnaeus)) entered Palauli Bay, and, upon approaching the beach, left small round pieces of their flesh as gifts to Tautunu, chief of that community. Evidence of this sacrifice was found by the people who caught the atu and observed fresh, round wounds on their sides.

This legend provides one of many explanations that have been advanced regarding the causes of such wounds on large pelagic fishes as well as on whales and porpoises. This paper presents evidence that many crater wounds, crescentic wounds, and the resulting scars on pelagic fishes (Figure 1), and open pit wounds and resulting scars on cetaceans are the results of bites inflicted by the small squaloid shark, *Isistius brasiliensis* (Quoy and Gaimard). (A second species, *Isistius plutodus*, was described by Garrick and Springer (1964) from the Gulf of Mexico. Although nothing is known of the behavior of

this species, which is based on one specimen, it is probable that its feeding habits are similar to those of *I. brasiliensis*.)

Such wounds on fishes have been reported by Nemoto (1955), Iversen (1959), Guitart M. (1964), Klawe (1966), Bane (1969), and Machado Cruz (1969). The literature on open pit wounds and related scars on cetaceans is much more extensive, apparently beginning with the work of Collett (1886). Mackintosh and Wheeler (1929) and van Utrecht (1959) presented thorough discussions of these wounds and probable causes, and summarized the previous literature. Nemoto (1955) noted that some of the wounds observed on whales are similar to and probably have a common origin with those on fishes. He further stated that a cause other than lamprey attacks, the most commonly advocated agent, must be found to account for crescent-shaped scars and open pit wounds on cetaceans and fishes.

It was not always possible for me to determine whether published photographs and descriptions were of wounds and scars of the types which I attribute to *Isistius* bites. I have never seen wounds known to have been produced by lampreys and therefore cannot comment with any

¹ National Marine Fisheries Service, Hawaii Area Fishery Research Center, Honolulu, Hawaii 96812.




FIGURE 1.—Crater wounds on a large dolphin from the central Pacific.

authority on them. I believe, however, that Pike (1951) unknowingly but accurately described the differences between lamprey bites and *Isistius* bites on whales when he wrote: "The lampreys seem to leave two distinct types of wounds The first consists of a circular area in which the epidermis is completely abraded by the teeth of the sucking disc. In the center of this is a hole through the skin caused by the rasping tongue. In the other type the lamprey apparently rasps away the skin over the entire area with the result that there is a circular sore right down to the blubber and no periphery of skin which has been damaged but not eaten away." The second type and some of the wounds and scars illustrated by Pike are, I believe, attributable to *Isistius* bites.

Crater wounds have been reported in the literature cited on skipjack tuna; yellowfin tuna,




FIGURE 2.—A crater wound on the side of a swordfish caught in the Gulf of Mexico. (Photo by Martin Bartlett.)

Thunnus albacares (Bonnaterre); dolphin, *Coryphaena hippurus* Linnaeus; opah, *Lampris regius* (Bonnaterre); and swordfish, *Xiphias gladius* (Linnaeus) (Figure 2). In addition to these, I have seen crater wounds on albacore, *Thunnus alalunga* (Bonnaterre), and wahoo, *Acanthocybium solandri* (Cuvier), in the central Pacific. Biologists and fishermen in Hawaii have reported to me having seen them on kawakawa, *Euthynnus affinis* (Cantor); large jacks, *Caranx* sp.; rainbow runners, *Elagatis* sp.; and various species of marlins, *Istiophoridae*.

The cetaceans upon which crater wounds, crescentic wounds, or resultant scars have been reported were listed by van Utrecht (1959). Included were beaked whales, sperm whales, various species of porpoises, and nearly all of the baleen whales (order Mysticeti) except the right whales (family Balenidae) which apparently do not migrate out of cold polar waters. In Hawaiian waters, wounds and scars (Figure 3) are commonly seen on porpoises of the genera *Tursiops* and *Stenella*, and have been observed on a beaked whale, *Ziphius* sp., stranded on Oahu.

Dr. Donald W. Strasburg, during discussions several years ago, planted the idea that *Isistius* might be the cause of crater wounds on fishes. He had found (Strasburg, 1963) that the man-

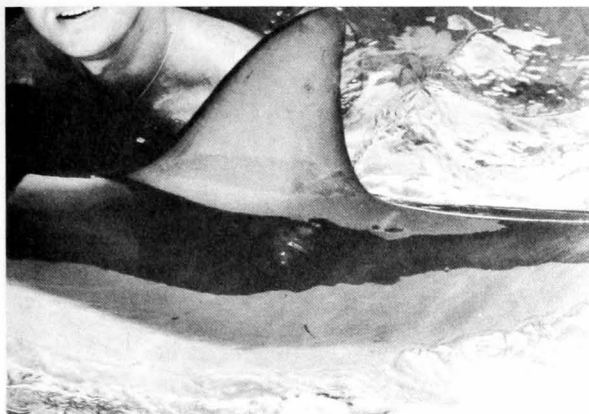

FIGURE 3.—Crescentic scar on a living porpoise, *Stenella roseiventris* Wagner, The Oceanic Institute, Makapuu, Hawaii.

dibular teeth of *Isistius* are shed as a unit and that the next set of replacement teeth are already erect and immediately functional when the previous set is shed. He wondered "... which aspects of *Isistius* biology require such a safeguard."

OBSERVATIONS

An opportunity to test the idea came in July 1969, during cruise 44 of the RV *Townsend Cromwell* of the NMFS, HAFRC (National Marine Fisheries Service, Hawaii Area Fishery Research Center). Nightly midwater trawl hauls were made along long 145° W between lat 14° N and 3° S in the central Pacific. The trawl catches contained occasional specimens of *Isistius*, some of which were alive but moribund when brought on board. I stated that this species of shark might be responsible for the crater wounds which we had observed on tunas a few hours earlier. This led John D. Fowler, Jr., research assistant aboard the *Townsend Cromwell*, to press the mouth of a moribund *Isistius* against the side of a dead fish, *Cubiceps* sp. The shark made a biting motion, producing a crescentic wound (Figure 4) that if completed would have been similar in size and shape to crater wounds observed on tunas. That shark could not be induced to repeat its performance, but Fowler's experiment led to further attempts to determine

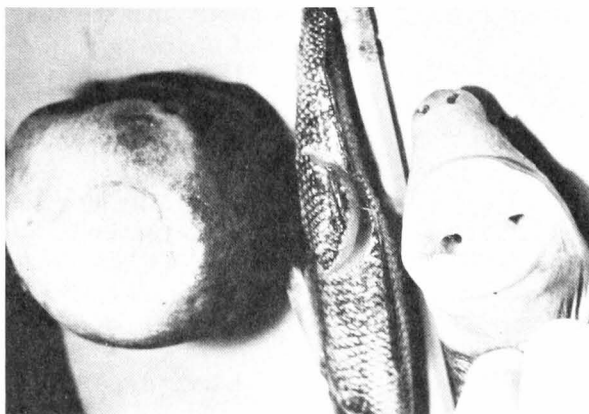


FIGURE 4.—A crater "wound" produced on the surface of a nectarine by pushing the teeth of a dead *Isistius* into the fruit and then rotating the body of the shark around the point of attachment. In the center is a crescentic "wound" produced by a living *Isistius* when its mouth was pressed against the side of the dead fish.

whether adaptations in structure for specialized feeding behavior existed in *Isistius*.

The basihyoid cartilage or "tongue" of *Isistius* was large and thick in contrast to that structure in galeoid sharks. It was also unusually movable; with a pencil I was able to push the tongue caudad to a point just anterior to the first exterior gill opening (Figure 5). In that position the posterior margin of the tongue was elevated (dorsad) until the tongue was nearly vertical, fitting closely against the roof of the mouth, and

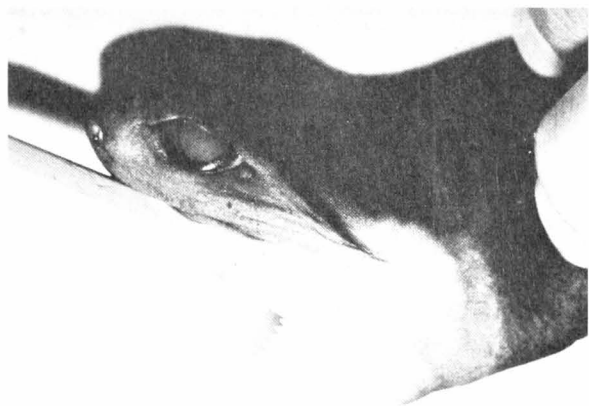

FIGURE 5.—A demonstration of the movability of the tongue of *Isistius*.

completely separating the mouth from the pharynx. Two ridges in the roof of the mouth corresponded to two grooves in the posterior margin of the tongue. This structural correspondence suggested that vertical positioning of the tongue was a normal occurrence. The movability of the tongue, as well as several other attributes described below, can only be demonstrated with specimens of *Isistius* that have not been fixed.

Observations of these anatomical characters led to the hypothesis that *Isistius* is capable of achieving a vacuum with its mouth on a smooth surface. Concurrently with the retracted, vertical positioning of the tongue, the lips protruded completely around the mouth. The fleshy lateral lips contained well-developed labial cartilages that caused them to be semirigid and, when protruded, to complete an ovoid of labial margins in a single plane (Figure 6). Such a structure in contact with a smooth surface enables the

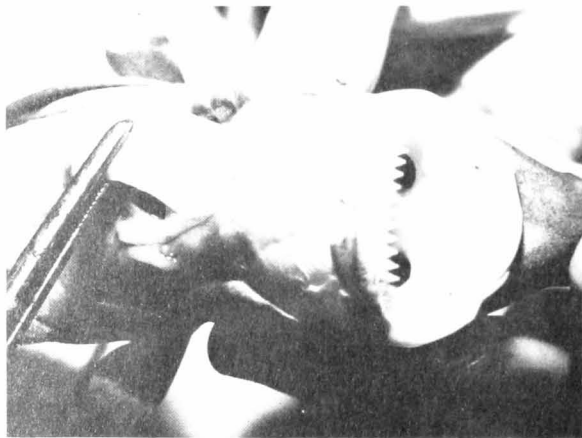

FIGURE 6.—A demonstration of the coracohyoideus muscles of *Isistius*. Note also the protruded lips, the internal openings of the spiracles, and the mandibular teeth.

shark to form a vacuum when the spiracles are closed and the tongue then retracted.

In order to further determine if behavioral retraction of the tongue was probable, dissections were made of the ventral surface of the shark just posterior to the mandible. The paired coracohyoideus muscles that insert on the tongue were unusually large in *Isistius* (Figure

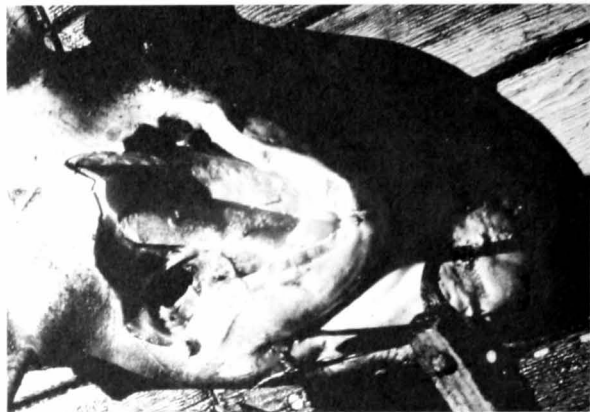


FIGURE 7.—Exposed coracohyoideus muscles of a large whitetip shark, central Pacific.

6). A comparative dissection of a large, fresh, whitetip shark, *Carcharhinus longimanus* (Poey) was made (Figure 7); the cross sectional areas in *Isistius* were estimated to be four times those of the same muscles in the whitetip shark, both relative to the total lengths of the sharks. Pulling caudad on the exposed coracohyoideus muscles of *Isistius* caused the tongue to retract to the nearly vertical position noted before; concurrently, the mouth gaped and the lips protruded. The tongue of the whitetip shark was not movable and pulling on the coracohyoideus muscles did not retract it.

Later I attempted to repeat Fowler's experiment by holding the mouth of a living *Isistius* against the side of a gempylid fish. In this case, the shark did not make a biting motion but, instead, the spiracles closed, the head flattened slightly, and an oral vacuum was formed by means of which I was able to lift the gempylid from the table with no other support.

It seemed that the remaining evidence needed to indict *Isistius* would be the presence of hemispherical plugs of fish flesh in their stomach contents. This evidence was found when two *Isistius* caught subsequently on the same cruise were found to contain single plugs of flesh of appropriate size and shape. One of these plugs was from a relatively large fish, judging from the thickness of the myomeres; the other was from a squid. During a later cruise in the same area, Reginald M. Gooding, fishery biologist,

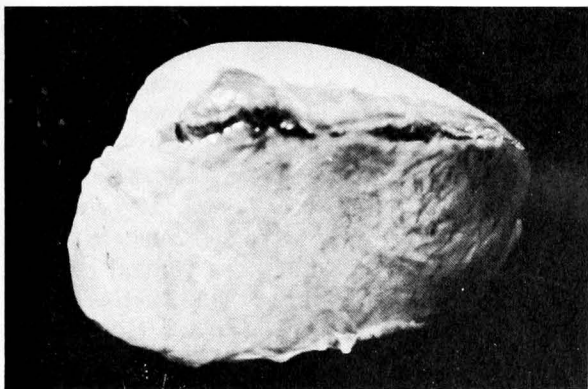

FIGURE 8.—A hemispheroidal plug of unidentified fish flesh from the stomach of an *Isistius*, central Pacific.

found a very fresh plug of fish flesh complete with integument and some scales (Figure 8). The fishes from which these plugs were bitten have not been identified. In order to find such plugs, it is necessary to examine *Isistius* immediately after capture because digestion will usually continue for a time after the specimen is placed in formaldehyde or a freezer.

DISCUSSION

Further evidence relating *Isistius* to wounds on fishes may be present in a photograph (Figure 9) of a crescentic wound on the caudal fin of a swordfish (M. R. Bartlett, personal communication). The deep crescentic cut is opposed by an arc of small dents and scars. The size and arrangement of these correspond to the small, hooked upper teeth of *Isistius* (Figure 6). In addition, a series of white scratches extending from the small arc toward the crescentic cut appear to have been made by the upper teeth as the shark backed away from the incomplete bite. In this case, the shark's mandibular teeth must have encountered the large, bony ray in the edge of the caudal fin. The same fin bore an entire, cut-out wound near the posterior border (Figure 10).

The geographical distribution of records of *Isistius brasiliensis* (Strasburg, 1963; Parin, 1964) corresponds well with the general distributions of the species of fishes which bear crater wounds. Several authors (Mackintosh and



FIGURE 9.—A crescentic wound on the caudal fin of a swordfish caught in the Gulf of Mexico. Note the arc of small dents opposite the cut, and the scratches produced by the shark's upper teeth as it backed away from the incomplete wound. (Photo by Martin Bartlett.)

Wheeler, 1929; Pike, 1951; Nemoto, 1955; van Utrecht, 1959) have noted that fresh wounds were seen only, or more frequently, on cetaceans caught in the warmer waters of their migrations and that those caught more poleward bore only healed or partially healed scars. This was evidence, they stated, that the animal producing the wounds was an inhabitant of warm water.

Some wounds on cetaceans described in the literature were undoubtedly produced by lampreys (Pike, 1951). The majority of catch records of lampreys in both the Pacific and Atlantic, however, are near shore and in temperate or cold waters which fits poorly the distribution of fishes and whales bearing fresh crater wounds.

The largest crater wounds recorded (Mackintosh and Wheeler, 1929) were 4 or 5 cm by 7 cm. The smallest I have seen were 1.2 cm by 2 cm. The smaller diameters of these correspond well with the bite-widths I have estimated for *Isistius* at the extremes of the known range of 14 to 50 cm, total lengths (Strasburg, 1963).

All of the *Isistius* stomachs examined aboard the *Townsend Cromwell* contained squid beaks and pieces of squid pens. Strasburg (1963) also

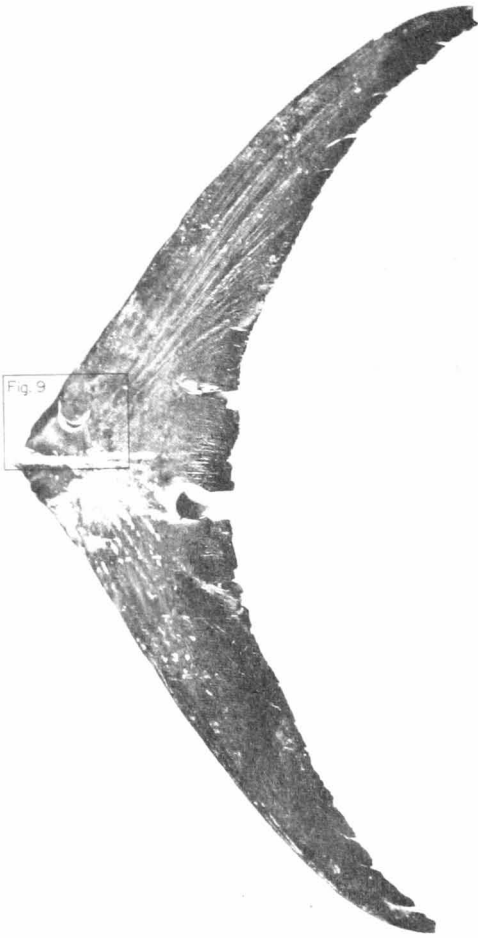


FIGURE 10.—The caudal fin of a swordfish caught in the Gulf of Mexico, showing a crescentic wound and a completed wound cut through the trailing edge of the fin.

found squid remains in most of the stomachs of preserved specimens he inspected, and calculated that the squids which were eaten were as large or larger than the sharks. He wondered how small sharks that apparently swim slowly could catch and capture such large, swift prey.

This question is also pertinent in considering how *Isistius* succeeds in contacting fast-swimming animals such as tunas, marlins, or porpoises. It would appear to be no problem for *Isistius* to approach and make contact with basking or drifting whales or fishes. In the case of tunas, however, there is no evidence that they ever drift or stop swimming (Magnuson, 1970).

A possible sequence is that the potential prey, seeing *Isistius* as an object apparently suitable for food, makes the initial approach, identifies it at a short distance, rejects it as food, and veers off. At that instant, the shark may be able to achieve contact by means of a short dash.

It is also possible that the shark, to some degree, simulates other organisms such as squids in the pattern of its luminous ventral surface. A more remote possibility is that *Isistius* is mistaken by large teleosts for a cleaner, and is invited to make contact.

Large squids appear to be killed by *Isistius* more often than merely deprived of plugs of flesh. It may be that squids also make an initial approach but, unlike teleosts, do not veer off from their attack and are subsequently bested in the encounter.

Isouchi (1970) provided the only record of an *Isistius* eaten by a large teleost when he found a living shark in the stomach of *Scomberomorus* sp. This record indicates that *Isistius* is a potential food item; on the other hand, records of teleosts having ingested any species of small or young sharks are limited to five or six (S. Springer and M. R. Bartlett, personal communications). This certainly supports a hypothesis of usual rejection. Rejection of the young as food by teleosts, in fact, may account for the survival of most elasmobranch species, considering their extremely low reproduction rates and relatively low swimming speeds.

It may not be necessary to assume any complicated behavior patterns of *Isistius* or its prey; perhaps contacts by means of short dashes can be made during chance proximities. Thomas Dohl, The Oceanic Institute, Hawaii, has informed me that young porpoises of sizes that are assumed to be still nursing do not bear wounds or scars, but those which are larger do. Similar restriction of wounds and scars to older porpoises is suggested by the data of van Utrecht (1959). This may be simply a matter of an increased probability of encounter with time; but it may, on the other hand, indicate that porpoises are not attacked by *Isistius* until the porpoises become predatory on fish.

Several crescentic wounds which I have examined on tunas were made from a frontal attack

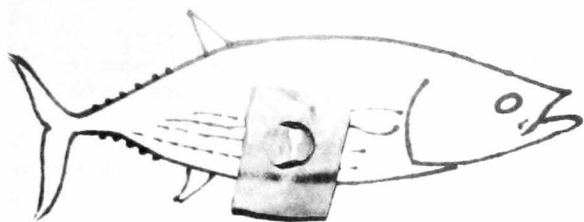


FIGURE 11.—An excised crescentic wound superimposed over a diagram of a skipjack tuna to indicate that the wound was made from a frontal attack, central Pacific.

position, that is, the shark and its prey were going in opposite directions when the wound was inflicted (Figure 11). Such crescentic wounds, as previously pointed out, are apparently the result of circumstances which do not allow the shark to complete the scooping out process. Besides providing support for the suggestion that the teleost makes the initial approach, the evidence of frontal attacks may explain the occurrence of wounds in which the plug of flesh is still attached to the bottom of the wound by a peduncle. Such wounds are common on cetaceans (Mackintosh and Wheeler, 1929; van Utrecht, 1959). In a frontal attack, the drag of water on the shark's body would cause it to rotate, in the manner of the hand of a clock, around the point of attachment until the shark was oriented in the same direction as its prey. This movement would cause the mandibular teeth to act in the manner of a melon-ball cutter and, if penetration was adequate, the crater wound would be completed.

To explore this possibility, I employed a nectarine (*Persicum* sp.) from the ship's galley since no large, dead fish was available at the moment. I pushed the teeth of a fresh, dead *Isistius* into the fruit and then rotated the body around that point. The result (Figure 4) was a neat, round, crater "wound" and the hemispheroidal "plug" in the shark's mouth with the small, hooked upper teeth securing it. If tooth penetration had been inadequate during such a sequence, the integument would be cut completely around but the plug would remain attached by a central peduncle. Necrosis of the plug would probably

follow, resulting in conditions described by Mackintosh and Wheeler (1929). They presented a hypothetical sequence beginning with a crescentic wound which developed, by gradual erosion of the flesh, to the open pit stage. The "flabby" pedunculate plug, they believed, was a stage in the healing process and was sloughed off near the completion of healing.

They pointed out that the most obvious cause of crescentic and open pit wounds was the bite of some fish, but no fish known to them possessed teeth or a mouth structure which would produce such wounds. They, therefore, returned to the assumption that the wounds were a result of microbial infections.

Except in the cases of attacks on squids when the prey is killed, it appears that *Isistius*, in biting pieces out of living cetaceans and fishes, qualifies as a temporary parasite in the same sense that a mosquito does.

ACKNOWLEDGMENTS

I want to acknowledge the contributions of many persons who provided unpublished records, specimens of wounds and scars, photographs, as well as ideas and encouragement during the preparation of this manuscript. My special thanks are extended to John D. Fowler, Jr., NMFS, HAFRC, who initiated the important experiments at sea.

LITERATURE CITED

- BANE, G. W.
1969. Parasites of the yellowfin tuna, *Thunnus albacares*, in the Atlantic Ocean. *Wasmann J. Biol.* 27: 163-175.
- COLLETT, R.
1886. On the external characters of Rudolphi's rorqual (*Balaenoptera borealis*). *J. Zool.* (London), p. 243-265.
- GARRICK, J. A. F., AND S. SPRINGER.
1964. *Isistius plutodus*, a new squaloid shark from the Gulf of Mexico. *Copeia* 1964: 678-682.
- GUITART M., D.
1964. Biología pesquera del Emperador o Pez de Espada, *Xiphias gladius* Linnaeus (Teleostomi: Xiphiidae) en las aguas de Cuba. [In Spanish, English synopsis.] *Poeyana*, Ser. B 1, 37 p.

- ISOUCHI, T.
1970. A cigar shark, *Isistius brasiliensis* from tropical water of the eastern Pacific. [In Japanese, English abstract.] Jap. J. Ichthyol. 17: 124-125.
- IVERSEN, E. S.
1959. Pelagic puzzle. Sea Frontiers 5: 175-178.
- KLAWE, W. L.
1966. Observations on the opah, *Lampris regius* (Bonnaterre). Nature (London) 210: 965-966.
- MACHADO CRUZ, J. A.
1969. Tentativa de diagnóstico etiológico de feridas em atuns - *Thunnus albacares* (Bonnaterre) - de Angola. [In Portuguese, English synopsis.] Junta Invest. Ultramar Estud. Ensaio Doc. 15, 8 p. + 6 fig.
- MACKINTOSH, N. A., AND J. F. G. WHEELER.
1929. Southern blue and fin whales. Discovery Rep. 1: 257-540 + 64 plates.
- MAGNUSON, J. J.
1970. Hydrostatic equilibrium of *Euthymus affinis*, a pelagic teleost without a gas bladder. Copeia 1970: 56-85.
- NEMOTO, T.
1955. White scars on whales. (1) Lamprey marks. Sci. Rep. Whales Res. Inst. Tokyo 10: 69-77.
- PARIN, N. V.
1964. Data on biology and distribution of pelagic sharks *Euprotomicrus bispinatus* and *Isistius brasiliensis* (Squalidae, Pisces). [In Russian, English summary.] Akad. Nauk SSSR Tr. Inst. Okeanol. 73: 163-184.
- PIKE, G. C.
1951. Lamprey marks on whales. J. Fish. Res. Board Can. 8: 275-280.
- STRASBURG, D. W.
1963. The diet and dentition of *Isistius brasiliensis*, with remarks on tooth replacement in other sharks. Copeia 1963: 33-40.
- VAN UTRECHT, W. L.
1959. Wounds and scars on the skin of the common porpoise, *Phocaena phocaena* (L.). Mammalia 23: 100-122.